

Cytodiagnosis of filarial infection on a non healing ulcer: an unusual presentation and review of literature

Akhtar S.¹, Gumashta R.^{2*}, Pande S.³, Maimoon S.⁴, Mahore S.⁵

^{1,4,5} Departments of Pathology, NKP Salve Institute of Medical Sciences & Research Centre, Nagpur, India

² Departments of Community Medicine, NKP Salve Institute of Medical Sciences & Research Centre, Nagpur, India

³ Departments of Dermatology, NKP Salve Institute of Medical Sciences & Research Centre, Nagpur, India

ABSTRACT

The authors report an unusual case of a 33-year-old Indian male adult, who sought treatment for skin infection, skin ulcer and oedema of leg for two years, but got no relief until he was incidentally diagnosed by scrape cytology for presence of

microfilaria in leg ulcer, blood and pleural fluid. The patient was fully cured after receiving complete treatment for filariasis.

Key words: filariasis, microfilaria, non-healing ulcer, leg, *Wucheria bancrofti*

*Corresponding author:

Department of Community Medicine,
N.K.P. Salve Institute of Medical Sciences & Research Centre,
Hingna Road, Nagpur, Maharashtra, India, Pin Code 440019
Tel.: +91- 8149929994
E-mail: rgumashta@yahoo.com (Raghvendra Gumashta)

Received: 1.09.2012

Accepted: 4.10.2012

Progress in Health Sciences

Vol. 2(2) 2012 pp 195-199.

© Medical University of Bialystok, Poland

INTRODUCTION

Filariasis is a disabling parasitic disease. Cytology has an important role in the diagnosis of sub-clinical filariasis. Such cases are often not identified in time for prompt treatment and cure. The ova and fragments of the adult worms of *Wuchereria bancrofti*, have been reported in exfoliative as well as aspiration cytology and are useful in cytological detection of bancroftian filariasis.

A wide range of parasitic infections can involve the skin and subcutaneous tissues, which, being species dependent may be transient. The parasite passes through the skin on its migration to the blood stream and thereafter to a specific target organ, or the infection may be localized to the skin. In the latter infections, the skin may be the primary site of infection or there may be a secondary invasion of the skin [1,2]. All parasitic groups (protozoa, trematodes, cestodes, nematodes and arthropods) have species that can involve the skin or subcutaneous tissues. Various nematode species, often zoonotic species, infect humans accidentally and can cause subcutaneous lesions. Nematode species infecting the skin include *Gnathostoma* and the filarial species, *Loa loa*, *Onchocerca volvulus*, *Mansonella streptocerca* and *Dirofilaria* spp [3].

Case Presentation

Dated 25.08.2009: A 33-year-old male presented to Skin OPD (Out Patient Department) of N.K.P. Salve Institute of Medical Sciences & Research Centre and Lata Mangeshkar Hospital, Nagpur (Maharashtra, India), with complaints of fever, rigors, swelling of right leg and ulcer on shin of right leg over the previous five days (Fig. 1).

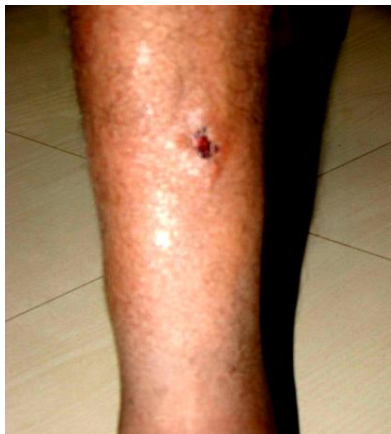

Figure 1. Clinical photo of patient showing ulcer on right leg with surrounding edema

He informed the staff that he'd had similar symptoms two years earlier, for which he sought

treatment from local practitioners. As per the prescription papers shown by the patient, he was prescribed antibiotics, antipyretics and anti-inflammatory drugs along with incision and drainage of pus. However, he developed similar complaints and hence sought treatment in the tertiary health care hospital. He was advised admission to the Dermatology Ward. He agreed to come the next day for hospital admission.

Dated 26.08.2009: He was admitted to the Skin Ward.

On examination: Diffuse non-pitting edema of right lower limb below knee joint, hypertrophic oedematous skin with an ulcer measuring 1cm x 0.5 cm on the antero-medial aspect of right leg and enlarged right inguinal lymph nodes were found. The base of the ulcer showed necrotic blood-filled material.

Personal history: The patient was a tobacco chewer for 15 years and was also taking alcohol for the last 10 years.

Pathology Investigations-

- (a) Scrape cytology of the ulcer showed the presence of microfilaria (*Wuchereria bancrofti*) morphologically diagnosed on a binocular research microscope under 100x magnification (Fig. 2).

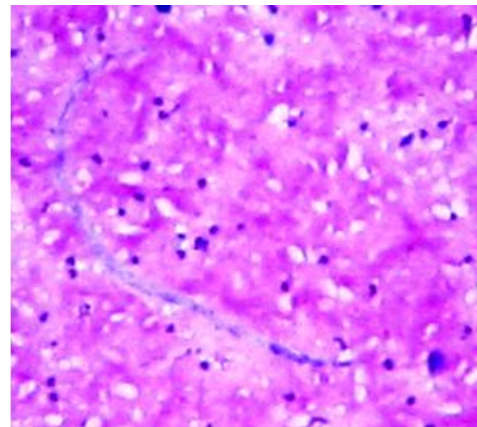


Figure 2. Scrape cytology of ulcer showing presence of microfilaria (H&E stain x400)

- (b) Following the scrape cytology report, further tests—Complete Blood Count (CBC) with Peripheral Smear (PS), Erythrocyte Sedimentation Rate (ESR) & Random Blood Sugar (RBS)—were performed. Peripheral Smear after 'Hetrazan Tablet' (Diethyl Carbamazine) provocation showed the presence of microfilaria (Fig. 3). Total Leukocyte Count was 12,800. Differential Count showed 12% Eosinophil. Absolute Eosinophil Count was 1,536 per cubic millimeter. FNAC (Fine Needle Aspiration Cytology) of Lymph Node done by

non-institutional private pathologist and was reported as 'No specific pathology seen'. Other investigations were within normal limits.

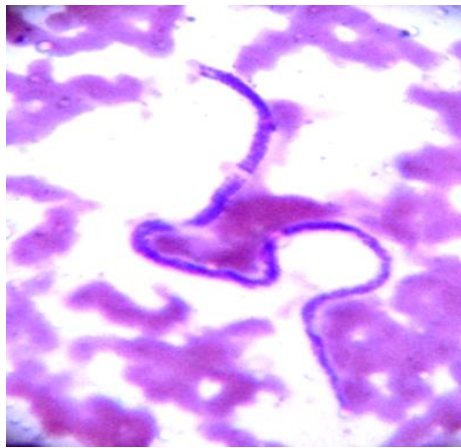


Figure 3. Peripheral smear showing presence of microfilaria (Leishman's stain X400)

- (c) Chest X-ray of patient showed pleural effusion, which was tapped and sent for cytology. The pleural fluid also revealed presence of microfilaria. (Fig. 4).

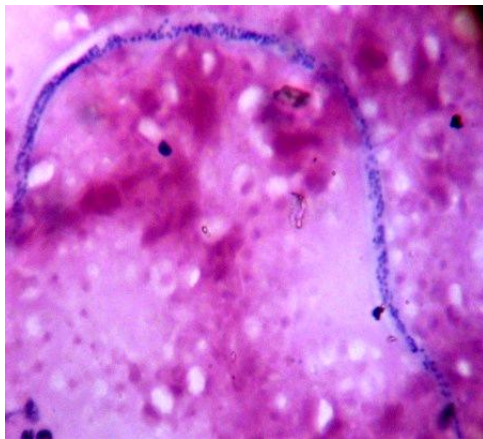


Figure 4. Pleural effusion cytology showing presence of microfilaria (H&E stain x400)

Dated 26.08.2009: The patient was put on Diethyl Carbamazine therapy and other supportive drugs. He showed signs of improvement.

Dated 27.08.2009: Patient left the hospital against medical advice since he was feeling very well and was homesick.

Follow-up: He continued to come in for follow-up visits in the Skin OPD (Out Patient Department) and fully responded to treatment by the end of the third week of September, 2009.

Diagnosis: Microfilaria infestation of right leg ulcer, blood and pleural fluid

DISCUSSION

Bancroftian filariasis produces a wide spectrum of clinical manifestations. The acute phase is characterized by fever, lymphangitis, lymphadenitis, epididymo-orchitis, and funiculitis. Headache, backache, muscle pain, insomnia, anorexia, urticarial rash, malaise, nausea and fatigue are common complaints. Eosinophilia and microfilaraemia are common in the acute phase. The chronic stage of bancroftian filariasis is characterized by lymphadenopathy, lymphedema, hydrocele and elephantiasis [4]. A trivial number of infected individuals in endemic areas remain asymptomatic throughout their lives [4] and are traditionally classified as 'endemic normal' [5].

In the recent era, the traditional classification of filarial disease has been challenged. The overtore of assays for circulating filarial antigen, the innovation of occult lymphatic pathology and renal disease in asymptomatic microfilaremics and the recognition of the role of bacterial infection in the pathogenesis of acute and chronic disease suggests that the old classification based on presence or absence of microfilaremia and/or chronic pathology is outdated. It is no longer wise to think of individuals as having filarial 'infection' without 'filarial disease' for the same reason—many of the former will have evidence of 'covert disease' if the studies are rigorous enough [5]. Considerable numbers of patients never go through tests for filarial infection because they are never included in epidemiological studies, nor do they present features typical of filariasis.

A review of literature reveals detection of microfilaria in most of the commonly performed cytological specimens, and frequently they are incidental. Microfilaria have been detected in cervicovaginal smears [6], endometrial smears [7], nipple secretions [8], ovarian cyst fluid [6], breast aspirates [9], hydrocele fluid [10], epididymal aspirates [11], urine samples [12], lung aspirates [13], pleural fluid [14], bronchial washings [6], ascitic fluid [15], intra-operative peritoneal fluid [16], lymph node aspirates [17,18], thyroid aspirates [19], salivary gland aspirates [20], bronchial brushings [21], laryngeal and pharyngeal brushings [22], gastric brushings [23], pericardial fluid [24], cutaneous nodule [25], soft tissue nodule [26], oral and skin ulcers [27], bone marrow aspirates [28], brain aspirates [29], joint aspirates [30], fine needle aspirates [31], esophageal stricture [32] and breast aspirates [33,34]. Microfilariae have been reported in association with neoplastic lesions such as anaplastic astrocytoma of thalamus [29], low grade astrocytoma of C6-D1 spinal segment [29], craniopharyngioma of third ventricle [29], carcinoma of pharynx [22], and carcinoma of breast [4].

Wuchereria bancrofti is the most widespread filarial parasite, accounting for 90% of filarial infection worldwide and in the Southeast Asia region

[5]. In most studies and in most of the reported cases, microfilaria in the cytological smears were identified as *Wuchereria bancrofti* [4]. Diagnosis of filariasis in cytological smears can also be made by presence of fragments of adult female or male worms and ova of the filarial organism with or without simultaneous presence of microfilaria.

As the parasite circulates in the lymphatic and vascular systems, appearance of filarial organism in tissue fluids and exfoliated surface material probably occurs due to conditions causing lympho-vascular obstruction resulting in extravasations of blood and release of microfilariae. Such aberrant migration to these dead-end sites is probably determined by local factors, such as lymphatic blockage by scars or tumors and damage to the vessel wall by inflammation, trauma or stasis [12]. Cytology has an important role in diagnosis of sub-clinical filariasis, although cytological diagnosis is often not requisitioned. Most cases of cytologically diagnosed filariasis are clinically unanticipated. Therefore, the clinicians and pathologists need to be more vigilant, especially in the endemic zone(s) of filariasis, for early diagnosis cum treatment of the cases. It shall ensure avoidance of complications and associated ailments at a later date.

Acknowledgements

We acknowledge the contribution of technical staff of Department of Pathology and Skin OPD of NKP Salve Institute of Medical Sciences & Research Centre, Nagpur, Maharashtra, India.

Conflict of Interest: None declared.

REFERENCES

1. Duke BO. Onchocerciasis. *BMJ*. 1968 Nov; 4 (1): 301.
2. Dreyer G, Addiss D, Gadelha P, Lapa E, Williamson J, Dreyer A. Interdigital skin lesions of the lower limbs among patients with lymphoedema in an area endemic for bancroftian filariasis. *Trop Med Int Health*. 2006 Sep; 11(9): 1475-81.
3. Darge K, Büttner DW. Ivermectin treatment of hyperreactive onchodermatitis (sowda) in Liberia. *Trop Med Parasitol*. 1995 Dec; 46(4): 206-12.
4. Nutman TB, Kumaraswami V. Regulation of the immune response in lymphatic filariasis: perspectives on acute and chronic infection with *Wuchereria bancrofti* in South India. *Parasite Immunol*. 2001 Jul; 23(7): 389-99.
5. Melrose WD. Lymphatic filariasis: New insights into an old disease. *Int J Parasitol*. 2002; Jul 32(8): 947-60.
6. Walter A, Krishnaswami H, Cariappa A. Microfilariae of *Wuchereria bancrofti* on cytologic smears. *Acta Cytol*. 1983 Jul-Aug; 27(4): 432-6.
7. Affandi MZ. Microfilaria in the endometrial smear. *Acta Cytol* 1980 Mar-Apr; 24(2):173-4.
8. Lahiri VL. Microfilariae in nipple secretions. *Acta Cytol*. 1975 Mar-Apr; 19(2):154.
9. Kapila K, Verma K. Diagnosis of parasites in fine needle breast aspirates. *Acta Cytol*. 1996 Jul-Aug; 40(4):653-6.
10. Vassilakos P, Cox JN. Filariasis diagnosed by cytologic examination of hydrocele fluid. *Acta Cytol*. 1974 Jan-Feb; 18(1): 62-4.
11. Jayaram G. Microfilariae in fine needle aspirates from epididymal lesions. *Acta Cytol*. 1987 Jan-Feb; 31(1):59-62.
12. Fuglsang H, Anderson J. Microfilariae of *Onchocerca volvulus* in blood and urine before, during, and after treatment with diethyl- carbamazine. *J Helminthol*. 1974 Jun; 48(2): 93-7.
13. Avasthi R, Jain AP, Swaroop K, Samal N. Bancroftian microfilariasis in association with pulmonary tuberculosis. Report of a case with diagnosis by fine needle aspiration. *Acta Cytol*. 1991 Nov-Dec; 35(6):717-8.
14. Marathe A, Handa V, Mehta GR, Mehta A, Shah PR. Early diagnosis of filarial pleural effusion. *Indian J Med Microbiol*. 2003 Jul-Sep; 21(3):207-8.
15. Mehrotra R, Gupta OP, Gupta RK. Filarial ascites clinically mimicking malignancy. *Acta Cytol*. 1996 Nov-Dec; 40(6):1329-30.
16. Sinha BK, Choudhary M, Sinha R. Microfilaria in peritoneal fluid from an amicrofilaremic, pregnant woman. *Acta Cytol*. 2001 Sep-Oct; 45(5):898-9.
17. Sah SP, Agarwal CS, Mishra A, Rani S: Chance finding of an adult filarial worm in lymph node. *J Nepal Medical Assoc* 1999; 38:45-7.
18. Sah SP, Rani S, Mahato R. Microfilariae in lymph node aspirates. *Acta Cytol*. 2002 Jan-Feb; 46(1): 73-5.
19. Pandit AA, Prayag AS. Microfilaria in thyroid aspirate smear: an unusual finding. *Acta Cytol*. 1993 Sep-Oct; 37(5):845-6.
20. Sahu KK, Pai P, Raghuveer CV, Pai RR. Microfilaria in a fine needle aspirate from the salivary gland. *Acta Cytol*. 1997 May-Jun; 41(3): 954.
21. Anupindi L, Sahoo R, Rao RV, Verghese G, Rao PV. Microfilaria in bronchial brushings cytology of symptomatic pulmonary lesions. A report of two cases. *Acta Cytol*. 1993 May-Jun; 37(3):397-9.
22. Munjal S, Gupta JC, Munjal KR. Microfilariae in laryngeal and pharyngeal brushing smears from a case of carcinoma of the pharynx. *Acta Cytol*. 1985 Nov-Dec; 29(6):1009-10.
23. Singh M, Mehrotra R, Shukla J, Nigam DK. Diagnosis of microfilaria in gastric brush cytology. A case report. *Acta Cytol*. 1999 Sep-Oct; 43(5):853-5.

24. Charan A, Sinha K. Constrictive pericarditis following filarial effusion. *Indian Heart J.* 1973 Jul; 25(3): 213-5.
25. Dey P, Walker R. Microfilariae in a fine needle aspirate from a skin nodule. *Acta Cytol.* 1994 Jan-Feb; 38(1): 114.
26. Pandit AA, Shah RK, Shenoy SG. Adult filarial worm in a fine needle aspiration of a soft tissue swelling. *Acta Cytol.* 1997 May-Jun; 41(3): 944-6.
27. Firfer BL, Nadimpalli VR, Lembli CM. Microfilaria of *Wuchereria bancrofti* in cytologic smears of oral ulcers. *Acta Cytol.* 1994 Jul-Aug; 38(4): 665-6.
28. Sharma S, Rawat A, Chowhan A. Microfilariae in bone marrow aspiration smears, correlation with marrow hypoplasia: a report of six cases. *Indian J Pathol Microbiol.* 2006 Oct;49(4):566-8.
29. Aron M, Kapila K, Sarkar C, Verma K. Microfilaria of *Wuchereria bancrofti* in cyst fluid of tumors of the brain: a report of three cases. *Diagn Cytopathol.* 2002 Mar; 26(3):158-62.
30. Weinberger A, Schumacher HR, Weiner DJ. Intraarticular microfilariae in laboratory animals. *Arthritis Rheum.* 1979 Oct; 22(10): 1142-5.
31. Mallick MG, Sengupta S, Bandopadhyay A, Chakraborty J, Ray S, Guha D. Cytodiagnosis of filarial infections from an endemic area. *Acta Cytol.* 2007 Nov-Dec; 51(6): 843-9.
32. Rawal A, Hayer J, Dey P. Microfilaria in esophageal stricture. *Acta Cytol.* 2002 Jan-Feb; 46(1): 70-1.
33. Sehri P, Krishnananda G, Gupta A, Mukherjee A. Breast filariasis - a case report. *Indian J Pathol Microbiol.* 2000 Jul; 43(3): 363-4.
34. Mehrotra R, Singh M, Javed KZ, Gupta RK. Cytodiagnosis of microfilaria of the breast from a needle aspirate. *Acta Cytol.* 1999 May-June; 43(3): 517-8.